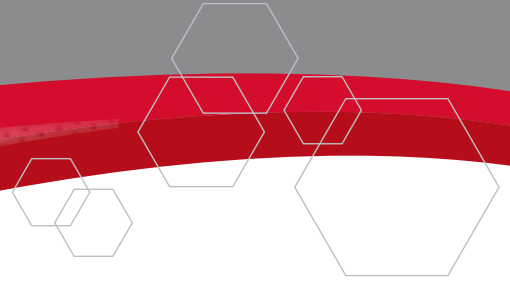
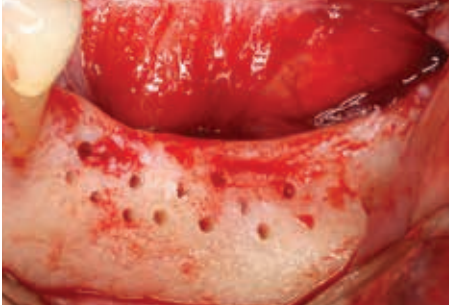

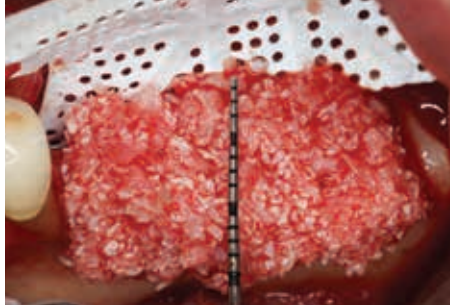
CASE STUDY: Ridge Augmentation Using Reinforced PTFE Mesh



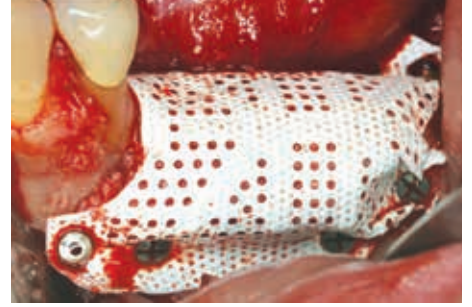Case Photos Provided by Istvan Urban DMD, MD, PhD



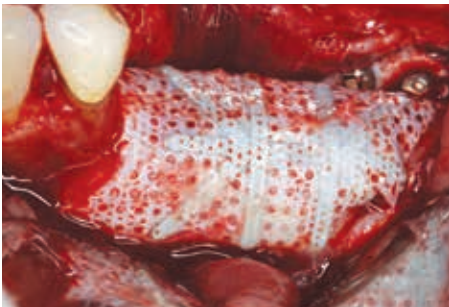1. Labial view of an atrophic posterior mandibular area.



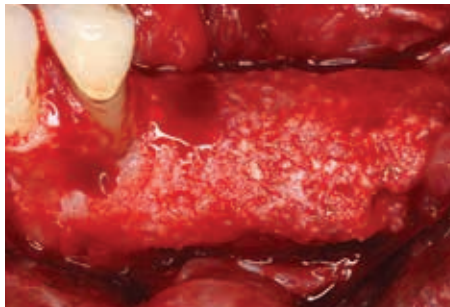
2. A 1:1 mixture of autogenous and xenogenic bone graft is placed on the ridge. Cortical bone was perforated, and an RPM Reinforced PTFE Mesh was secured on the lingual side before applying bone graft.



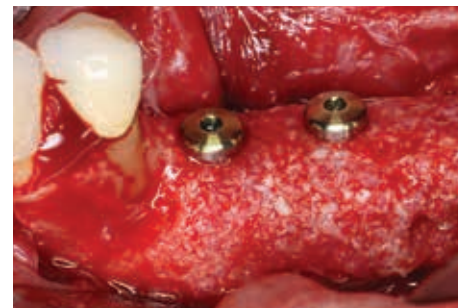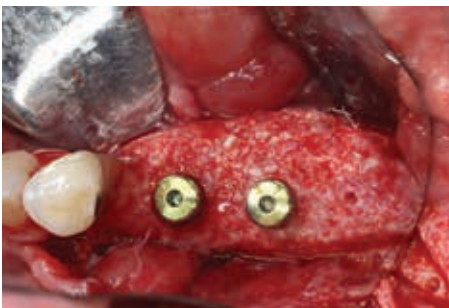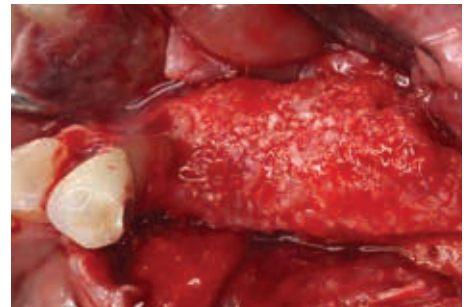
3. An RPM is secured over the graft with titanium pins and screws.



4. After 9 months of healing the augmented site is exposed, and the RPM will be removed.



5. & 6. Labial and occlusal views of the regenerated bone after 9 months of healing.



7. & 8. Labial and occlusal views of two implants placed into regenerated bone.